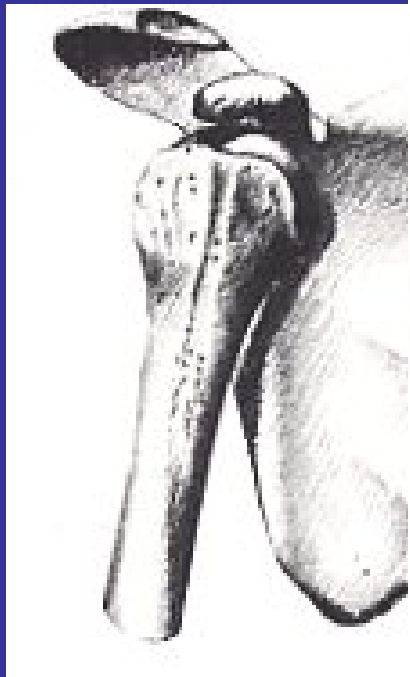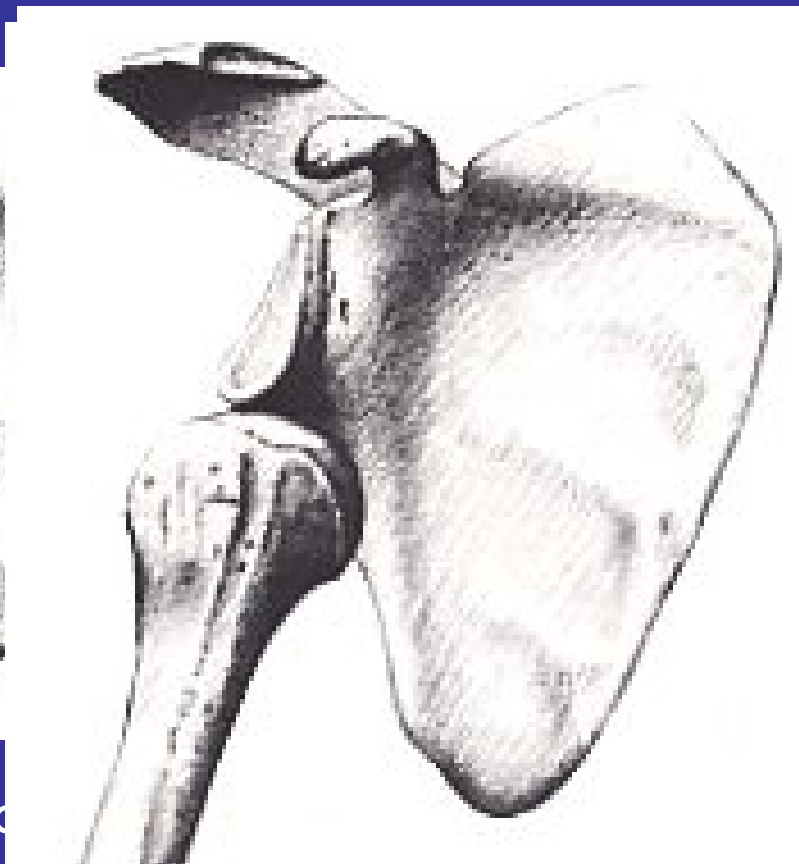


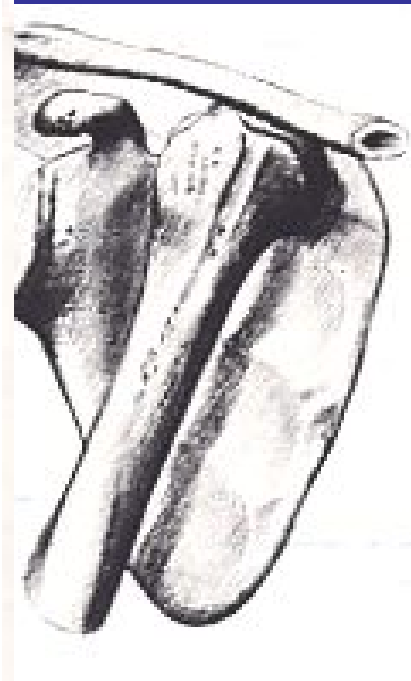
LUSSAZIONE SCAPOLO-OMERALE



sottocoracoideo



sottoglenoideo



sottoclavicolare

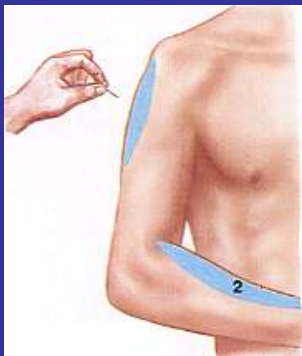
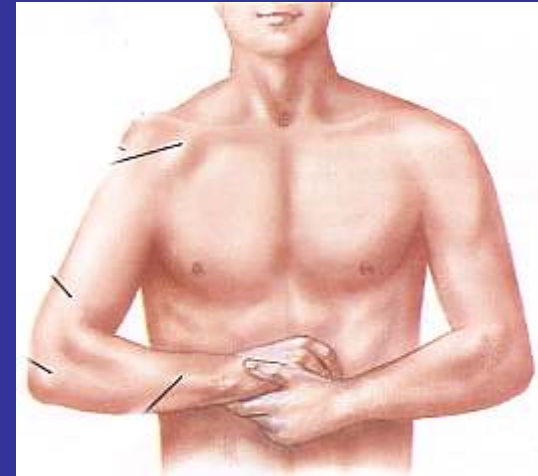CLINICA

✓ dolore intenso

✓ impotenza funzionale completa

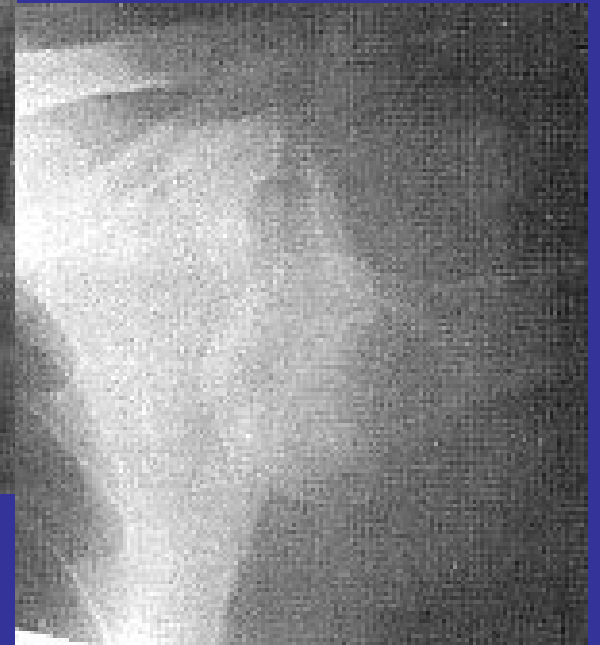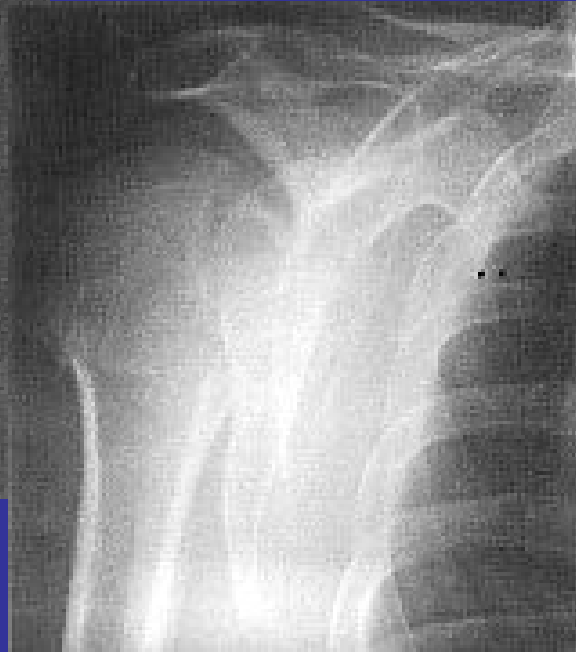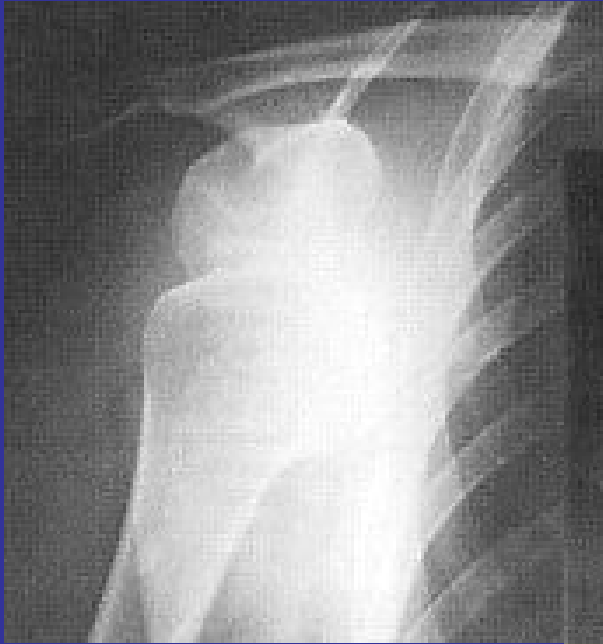✓ alterazione del profilo della spalla

Il braccio è abdotto ed intrarotato, sorretto dall'arto controlaterale



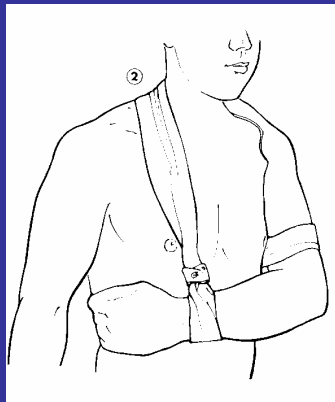
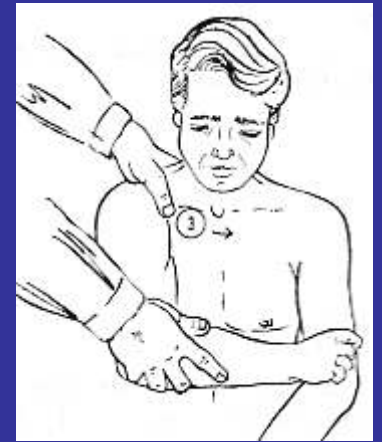
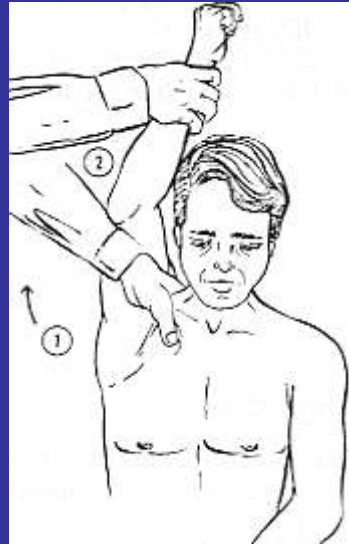
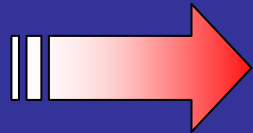
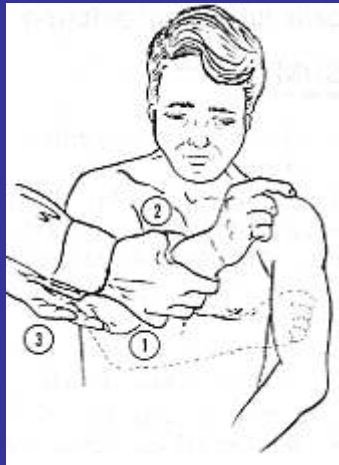L'abduzione del braccio è elastica

IMAGING



TERAPIA

RIDUZIONE

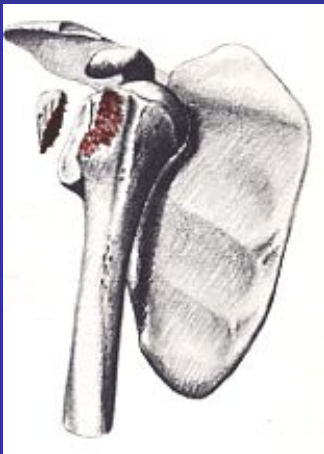


3 settimane!

COMPLICANZE

IMMEDIATE LOCALI

- ✓ lesione nervo circonflesso
- ✓ lesione dei vasi ascellari
- ✓ frattura del trochite



TARDIVE LOCALI

- ✓ spalla dolorosa cronica
- ✓ instabilità articolare
- ✓ lussazione recidivante
- ✓ artrosi